

Gastroliths in a pygmy hippopotamus (*Hexaprotodon liberiensis* MORTON 1844) (Mammalia, Hippopotamidae)

OLIVER WINGS, JEAN-MICHEL HATT, ANGELA SCHWARM & MARCUS CLAUSS

Abstract

During necropsy of a geriatric, female pygmy hippopotamus (*Hexaprotodon liberiensis*) from a zoo, a large amount of gravel was detected in the stomach. Reasons are outlined why this finding is no evidence for a gastric mill in hippopotamuses, but serves as a functional test of the hypothesis that hippopotamus stomach structures can act as sedimentation traps.

Key words: *Hippopotamus*, gastrolith, digestion, forestomach, particle size.

Gastrolithen in einem Zwergflußferd (*Hexaprotodon liberiensis* MORTON 1844) (Mammalia, Hippopotamidae)

Zusammenfassung: Während der Leichenschau eines alten weiblichen Zwergflußferdes (*Hexaprotodon liberiensis*) wurde eine große Menge Kies im Magen des Zootieres entdeckt. Es werden die Gründe aufgeführt, warum dieser Fund zwar kein Beweis für eine Magenmühle in Flußferden ist, aber als funktioneller Test der Hypothese dienen kann, daß die Magenstrukturen bei Flußferden Sedimentfallen darstellen.

Introduction

Gastroliths (stomach stones) occur in a variety of extant vertebrates, including birds, crocodylians, and pinnipeds (BAKER 1956, WHITTLE & EVERHART 2000, WINGS 2007). They can represent accidental ingestion, such as reported for domestic horses when fed not from hay racks but from the ground (HUSTED et al. 2005), aberrant ingestion in diseased animals (pica), or an attempt of the animal to alleviate a mineral deficiency (reviewed in WINGS 2007).

However, the occurrence of swallowed stones (geo-gastroliths sensu WINGS 2007) within herbivorous taxa is com-

monly related to a triturative and mixing function of ingesta. The gizzard in birds, filled with grit, is a well-known adaptation to grind up food matter in a so-called gastric mill and is functioning as a substitute for teeth (ZISWILER & FARMER 1972). Within terrestrial mammals, a presumptive muscular stomach has been reported in ant-eating taxa such as pangolins (*Manis* spp., Manidae) (NOWAK 1991) or giant anteaters (*Myrmecophaga tridactyla* LINNAEUS 1758, Myrmecophagidae) (GRIFFITHS 1968, OWEN 1857), whereas herbivorous mammals with well-developed teeth usually lack not only a muscular stomach, but also gastroliths.

Authors' addresses:

Dr. Oliver WINGS, Museum für Naturkunde der Humboldt-Universität zu Berlin, Invalidenstrasse 43, D-10115 Berlin, Germany; oliver.wings@web.de

Prof. Dr. Jean-Michel HATT, Clinic for Zoo Animals, Exotic Pets and Wildlife, Vetsuisse Faculty, University of Zurich, Switzerland

Dipl.-Biol. Angela SCHWARM, Leibniz Institute for Zoo and Wildlife Research (IZW) Berlin, Germany

PD Dr. Marcus CLAUSS, Clinic for Zoo Animals, Exotic Pets and Wildlife, Vetsuisse Faculty, University of Zurich, Switzerland

— Correspondence to: Clinic for Zoo Animals, Exotic Pets and Wildlife, Winterthurerstrasse 260, CH-8057 Zürich, Switzerland; mclauss@vetclinics.uzh.ch

Results and discussion

To the best of our knowledge, this is the first reported occurrence of a large amount of gravel in the digestive tract of a pygmy hippopotamus (*Hexaprotodon liberiensis* MORTON 1844). The wild-caught ♀ specimen had lived at the Zoological Garden of Zurich, Switzerland, for 40 years with a partner animal and had, during the course of its life, given birth to 15 offspring. It was kept in an indoor enclosure with smooth tile and concrete surfaces and had access to an indoor water pool. Additionally, the animals had regular access to a 200 m² outside enclosure with a water pool; the ground of the outside enclosure consists of natural soil with high amounts of gravel. The animals were consistently fed a diet of lucerne hay, mixed fruits and vegetables, and herbivore pellets. They had routinely been fed vegetables as well as pellets on the ground of the outside enclosure. In 2007, the ♀ was euthanized due to progressive deterioration of general condition over the course of several weeks, with listlessness, apparent blindness, and hindleg paralysis.

The gastrointestinal tract of hippopotamuses is characterised by a voluminous forestomach with two blind sacs and a connecting chamber, which leads into the glandular stomach (LANGER 1976, 1988). Hippopotamuses rely on extensive bacterial fermentation of the ingested plant material in these forestomach compartments (reviewed in CLAUSS et al. 2004a). However, neither the motility and the mechanical function of the hippopotamus forestomach, nor the function of the two blind sacs, have been investigated in detail. CLAUSS et al. (2004a) produced limited evidence that hippopotamuses excrete larger particles faster from their digestive tract than smaller particles. The selective retention or excretion of large or small food particles can be linked to the specific density of the particles (smaller particles being of a higher specific density) and the anatomical position of gastrointestinal structures in relation to gravitation (CLAUSS 2004). The blindsacs of the hippopotamus forestomach, with their dorsal in- and outflow, and their ventral blind ends have been interpreted as sedimentation traps in which smaller particles of a higher specific density might be particularly retained (CLAUSS et al. 2004a).

At necropsy of the pygmy hippopotamus, a polycystic condition of the kidneys was the major finding; the gastrointestinal tract did not show signs of inflammation. Both blind sacs of the forestomach were found to be filled not only with food particles, but also with large amounts of gravel (Figs. 1, 2). These gastroliths were composed of quartz, quartzite, and small amounts of marly limestone. They had a mean diameter ranging between 2 and 10 mm, a subangular outline and a dull surface. The colour varied between white, grey, and black. The gastroliths closely resembled the gravel present in the soil of the outside enclosure, although the limestone fraction was considerably lower in the gastroliths, pre-

sumably due to dissolution of limestone by stomach acid. At 3.98 kg, this gravel represented 33 % of the total wet forestomach contents (11.91 kg) and 1.7 % of the total body mass (228 kg) of the animal.

Observers of the dissection immediately suspected that these gastroliths could represent a functional gastric mill, a second step of food particle size reduction, compensating for the fact that hippopotamuses are forestomach fermenters that do not ruminate.

Several reasons speak against this hypothesis.

- (1) The forestomach of the hippopotamus, including the blind sacs, is lined by a papillated, cutaneous mucosa (Fig. 2) similar to the rumen mucosa found in cattle. Such a mucosa lacks strong muscular tissue and is poorly suited to withstand the forces necessary to effect particle size reduction by grinding action of gastroliths in a gizzard-like structure. To maintain an avian style gastric mill, strong stomach muscles combined with a highly resistant koilin (keratinoid) layer in the gizzard are necessary (ZISWILER & FARMER 1972).
- (2) Given the allometric equation on the mass of gastroliths in birds in relation to body mass (in grams): gastrolith mass = 0.001 body mass^{1.20} established by WINGS & SANDER (2007), a total gastrolith mass of 2.7 kg would be expected in a 228 kg animal with a functional gastric mill. The gravel in the pygmy hippopotamus exceeded this value by 33 % — although compared to avian gastrolith masses, it would still be within variation range of functional gizzards.
- (3) The surface texture of the gravel in the forestomach was similar to the texture of pebbles in the animal enclosure. No abrasion or sphericity increase similar to the one documented e.g. for gastroliths in ostrich gizzards (WINGS & SANDER 2007) was apparent.
- (4) A functional gastric mill should result in an efficient particle size reduction. No difference in ingesta particle size between the forestomach blind sacs and the more distal stomach compartments was evident by visual inspection. With a combination of both dental mastication and a gastric mill, hippopotamuses should achieve a particularly efficient ingesta particle size reduction. However, in a study where faecal particle sizes in captive herbivores were compared, equids and the common hippopotamus (*Hippopotamus amphibius* LINNAEUS 1758) had the largest faecal particles of all species investigated (OKAMOTO 1997); compared to available data on wild ruminants (CLAUSS et al. 2002), the common hippopotamus has particularly large faecal particles, and this is not an effect of captivity, as faecal particle size does not differ between captive and free-ranging hippopotamus specimens

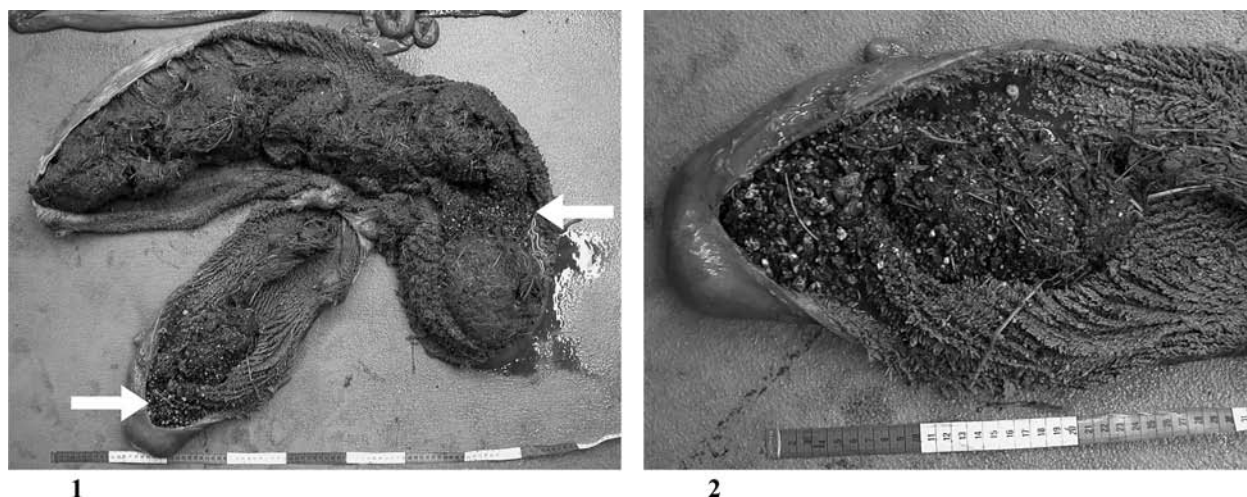


Fig. 1. The cut-open forestomach of the pygmy hippopotamus containing partly digested foodstuff and gastroliths (arrows) in the blind sacs. The top left segment is the connecting chamber; its end on the left leads to the glandular stomach that has been removed. Fig. 2. Close-up of one of the blind sacs, containing a high number of small gastroliths. Note also the papillated, cutaneous mucosa lining.

(CLAUSS et al. 2004b).

- (5) When compared to bird gastroliths (WINGS 2004, WINGS & SANDER 2007), the small size of the pebbles would have been inefficient in a gastric mill of an animal as large as a hippopotamus.
- (6) There are no literature reports on similar findings in extant or fossil hippopotamuses. Although inorganic components in the forestomach have not been explicitly looked for in hippopotamuses so far, during the investigation of the gastrointestinal tracts of free-ranging common hippopotamuses by LANGER (1976, 1988), no particular sand or stone deposits were noticed in the blindsacs (P. LANGER, pers. comm.). Therefore, the suspicion that the gravel found in the individual pygmy hippopotamus represents a functional gastric mill must be rejected.

However, the anatomical position of the gravel in the forestomach of the pygmy hippopotamus supports the hypothesis that the blindsacs of the hippopotamus forestom-

ach can act as sedimentation traps (CLAUSS et al. 2004a). The observation that another pygmy hippopotamus excreted sand and small stones in its faeces even after being confined to a sand-free indoor enclosure for a week (A. SCHWARM, pers. obs.), supports the notion that dense particles — like gravel or sand — can first be trapped and accumulate in these blind sacs, and then be released gradually over time due to forestomach contractions and displacement by ingesta. Over the subsequent months after the dissection of this pygmy hippopotamus, three more adult, captive animals were dissected by the last author, including the partner animal of the female described here. One animal did not have relevant amounts of sand or gravel in its forestomach, and the other two — including the partner animal — had moderate amounts of approximately 300–400 g of sand and gravel in the forestomach blind sacs, again corroborating that dense particles can accumulate here, and that pygmy hippos will ingest — deliberately or incidentally — sand or gravel from their enclosure, but do not depend on gastroliths in the sense of a gastric mill.

References

- BAKER, A. A. (1956): The swallowing of stones by animals. — *The Victorian Naturalist*, Melbourne, **73**: 82–95.
- CLAUSS, M. (2004): The potential interplay of posture, digestive anatomy, ingesta density and gravity in mammalian herbivores, or why sloths do not rest hanging upside down. — *Mammal Review*, Oxford, **34**: 241–245.
- CLAUSS, M., LECHNER-DOLL, M., & STREICH, W. J. (2002): Faecal particle size distribution in captive wild ruminants: an approach to the browser/grazer-dichotomy from the other end. — *Oecologia*, Berlin, **131**: 343–349.
- CLAUSS, M., SCHWARM, A., ORTMANN, S., ALBER, D., FLACH, E. J., KÜHNE, R., HUMMEL, J., STREICH, W. J., & HOFER, H. (2004a): Intake, ingesta retention, particle size distribution and digestibility in the hippopotamidae. — *Comparative Biochemistry and Physiology*, New York, **A139**: 449–459.
- CLAUSS, M., SCHWARM, A., ORTMANN, S., THIERER, D., HILDEBRANDT, T., HOHMANN, G., FLACH, E. J., KÜHNE, R., & HOFER, H. (2004b): Comparative analysis of physical and chemical characteristics of faeces from free-

- ranging and captive common hippopotami (*Hippopotamus amphibius*). — *Advances in Ethology*, Berlin, **38**: 26.
- GRIFFITHS, M. (1968): Echidnas. — New York (Pergamon), 282 pp.
- HUSTED, L., ANDERSEN, M., BORGGAAARD, O., HOUE, H., & OLSEN, S. (2005): Risk factors for faecal sand excretion in Icelandic horses. — *Equine Veterinary Journal*, London, **37**: 208–221.
- LANGER, P. (1976): Functional anatomy of the stomach of the *Hippopotamus amphibius*. — *South African Journal of Science*, Johannesburg, **72**: 12–16.
- — — (1988): The mammalian herbivore stomach. — Stuttgart, New York (G. Fischer), 557 pp.
- NOWAK, R. M. (1991): WALKER'S mammals of the world. — Baltimore (Johns Hopkins Univ. Pr.), 642 pp.
- OKAMOTO, M. (1997): Comparison of particle size in the feces of various herbivores. — *Journal of the Rakuno Gakuen University (Natural Sciences)*, Ebetsu, **22**: 151–153.
- OWEN, R. (1857): On the anatomy of the great ant-eater *Myrmecophaga jubata* (LINN.), Part II. — *Proceedings of the Zoological Society of London*, **25**: 22–23.
- WHITTLE, C. H., & EVERHART, M. J. (2000): Apparent and implied evolutionary trends in lithophagic vertebrates from New Mexico and elsewhere. — *New Mexico Museum of Natural History and Science Bulletin*, Albuquerque, **17**: 75–82.
- WINGS, O. (2004): Identification, distribution, and function of gastroliths in dinosaurs and extant birds with emphasis on ostriches (*Struthio camelus*). — Ph.D. thesis, University of Bonn, Bonn, 187 pp. — Accessible online at <http://nbn-resolving.de/urn:nbn:de:hbz:5N-04626>.
- — — (2007): A review of gastrolith function with implications for fossil vertebrates and a revised classification. — *Acta Palaeontologica Polonica*, Warszawa, **52**: 1–16.
- WINGS, O., & SANDER, P. M. (2007): No gastric mill in sauropod dinosaurs: new evidence from analysis of gastrolith mass and function in ostriches. — *Proceedings of the Royal Society, London*, **B274**: 635–640.
- ZISWILER, V., & FARNER, D. S. (1972): Digestion and the digestive system. — Pp. 343–430 in: FARNER, D. S., & KING, J. R. (eds.), *Avian Biology*, Vol. **2**. — London (Academic Press), 612 pp.

Received: 27. VIII. 2008; accepted: 11. IX. 2008.